

Excessive Pronation: A Major Biomechanical Determinant in the Development of Chondromalacia and Pelvic Lists

BRIAN A. ROTHBART, D.P.M., Ph.D.* AND LEW ESTABROOK, D.C.†

ABSTRACT

Based on statistical analysis of 97 chronic low back patients, a pelvic list model has been proposed explaining the correlation between leg length discrepancies (LLD) and sciatica. This model suggests that asymmetrical pronation patterns (one pedal arch dropping more than the contralateral pedal arch) initiates a forward downward rotation within the sacroiliac joint. Entrapment of the sciatic nerve between the piriformis muscle and sacrospinous ligament occurs. Clinically, paresis is observed: numbness, weakness and eventually paralysis of the affected limb. Based on this work, the authors have comprised a classification dividing LLD into two main categories: functional and anatomical. Functional LLD have been subdivided into two types of lists: static and dynamic. Treatment based on a combination of

chiropractic and podiatric therapy is presented with a 6-month follow-up. Analysis of the success in this tandem approach is very promising. Concurrently, a chondromalacia model is proposed explaining the pathomechanical events associated with oblique tracking patellar syndrome. The authors suggest that excessive pronation is the causative factor directing asynchronous rotation between the shank and femur. This forces the patella out of its normal tracking groove, which, in turn, generates erosion between the inferior margin of the patella and femoral epicondyles. (*J Manipulative Physiol Ther* 1988;11:373-379).

Key Indexing Terms: Leg Length Insufficiency, Sciatica, Patella, Chondromalacia Patellae, Podiatry, Chiropractic.

INTRODUCTION

One of the most perplexing anomalies affecting the back and lower extremity is the leg length discrepancy syndrome (LLDS). Few practitioners argue its existence; however, even fewer agree as to its etiology. Based on a preliminary study of 97 chronic low back patients, we propose a pelvic list model to explain LLDS. This model is collaborated by statistical data that suggests functional leg length discrepancies are commonly due to pelvic lists, which, in turn arise from asymmetrical pronation patterns. In addition, a second biomechanical model is presented delineating the pathomechanical events leading to chondromalacia. In this model, it is not the asymmetry but the severity of pronation that influences the development of chondromalacia.

Walking is a unique activity during which the body, step by step, teeters on the edge of catastrophe. Man's

bipedal mode of locomotion appears potentially catastrophic because only the rhythmic forward movement of the limbs keeps him from falling. The foot, being the base of support of the skeletal framework, plays an important role in gait. During early stance phase, the foot must be flexible so it can adapt to uneven ground surfaces. During late stance phase, it must be rigid to withstand the propulsive force generated by the big toe pushing off against the ground. Pronation and supination of the subtalar joint (Figure 1), the joint immediately below the ankle joint, gives the foot this dual capability. Pronation of the subtalar joint unlocks the foot (preparing it for heel-contact), while supination of the subtalar joint locks the foot (preparing it for toe-off (1-3)).

Ambulation begins as an internal-forward (horizontal plane) rotation of the pelvis around the weight-bearing hip. The total amount of this rotation varies from individual to individual about a mean of approximately 8° (4) (Figure 2). As the pelvis swings forward, the femur and tibia synchronously rotate internally. It is this internal shank rotation that generates rearfoot (subtalar joint) pronation at heel contact (5) (Figure 3).

* Private practice of podiatrics. † Private practice of chiropractic.

Submit reprint requests to: Brian A. Rothbart, D.P.M., Ph.D., 10833 Main, Bellevue, WA 98004.

Paper submitted June 10, 1987; in revised form July 15, 1987.

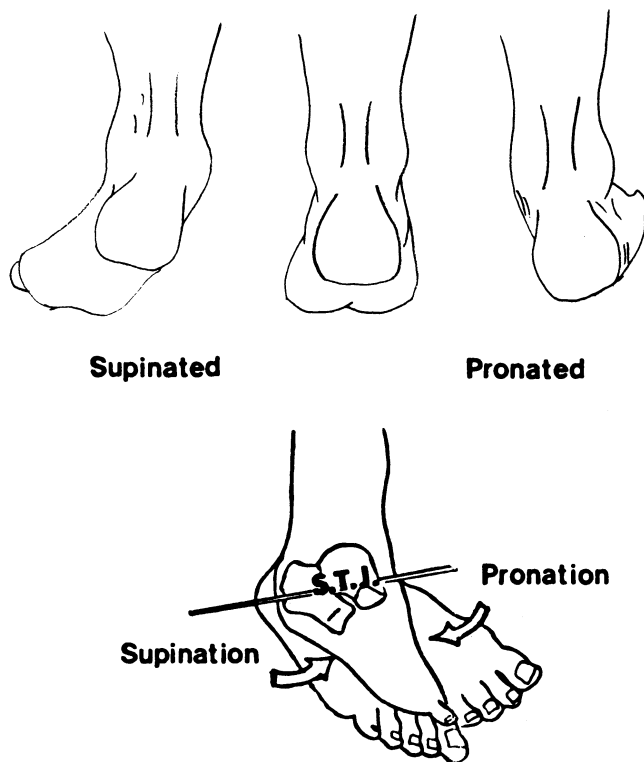


Figure 1. Neutral position.

Subtalar joint pronation has two important effects on the biomechanics of the foot: a) it acts as a directional torque transmitter, absorbing the axial rotation of the leg and thus preventing it from entering the foot and b) it unlocks and prepares the forefoot for heel contact by diverging the axes of the midtarsal joint (6, 7). One can easily demonstrate this shank to foot relationship by rotating the hips in a standing position. Counter-clockwise rotation of the hips internally rotates the right leg and pronates the right foot; the foot rolls inward as the arch prolapses (8, 9). Walking insouciantly on ice with a rapid cadence demonstrates the effect axial limb rotation has on a foot without a functional subtalar joint; e.g., the foot slips with each stride. From a causal point of view, pronation is a function of the pelvis, not the foot (10-12).

The above discussion presumes a normal functional relationship in which the range of pronation within the subtalar joint is dictated by pelvic rotation. However, an excessive range of foot pronation can result from structural weaknesses within the foot or shank. In such cases, the foot no longer follows the pronation pattern generated by the pelvis. This can lead to symptoms within the ankle, knee, hip and low back. A mechanical analogy is a bridge (back) with an unstable foundation (pronated foot). In time everything above the unsound

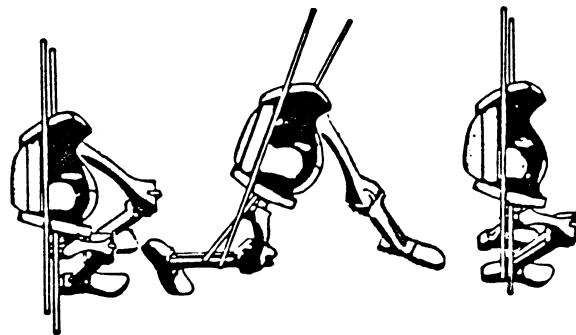


Figure 2. Note that forward rotation of the left pelvic girdle (superior axis) internally rotates the ipsilateral thigh and shank (inferior axis). (Adapted and reproduced with permission from V. T. Inman et al. *Human Walking*. I. Introduction. Baltimore: Williams & Wilkins, 1981).

foundation shifts (soft tissue changes) and eventually collapses (joint changes).

Pelvic List Model

The authors have chosen to divide pelvic lists into two categories: static and dynamic. We define static pelvic lists as a pathomechanical pelvis with no underlying pathological or congenital variances. The pelvic list is stable; the list does not alternate from side to side. In contrast, the authors define dynamic pelvic lists as a pathomechanical pelvis with overlying variances (e.g., congenital anomalies, musculoskeletal pathology). The pelvic list is unstable, and the list alternates from side to side. The pelvic list model only addresses the static list, which is an abnormal function of the sacroiliac joint ipsilateral to the foot hyperpronation. The ilia are rotated and fixed in an anterosuperior position (using the posterior superior iliac spine as the reference point). Motion palpation and AP weight-bearing radiographs, using the posterosuperior iliac spine as the anatomical landmark, correlate this vertical and rotational torquing to upper sacroiliac dysfunction (fixation), followed by abnormal motion and irritation.

The authors suggest that asymmetrical pronation patterns (variances from side-to-side of more than 2° of stance-phase pronation) is one of the primary biomechanical factors leading to a static (stable) pelvic list and sciatic nerve irritation. This statement is based on a preliminary study of 97 chronic low back pain sufferers. We theorize the following: pronation generates potential vertical limb displacement (functional short leg) by prolapsing (dropping) the inner longitudinal arch. Gravity and improper biomechanics then places the pelvic/sacroiliac (SI) joint at high risk to vertical and rotational displacement towards the functionally short leg. The pelvic list can lead to increased lordosis

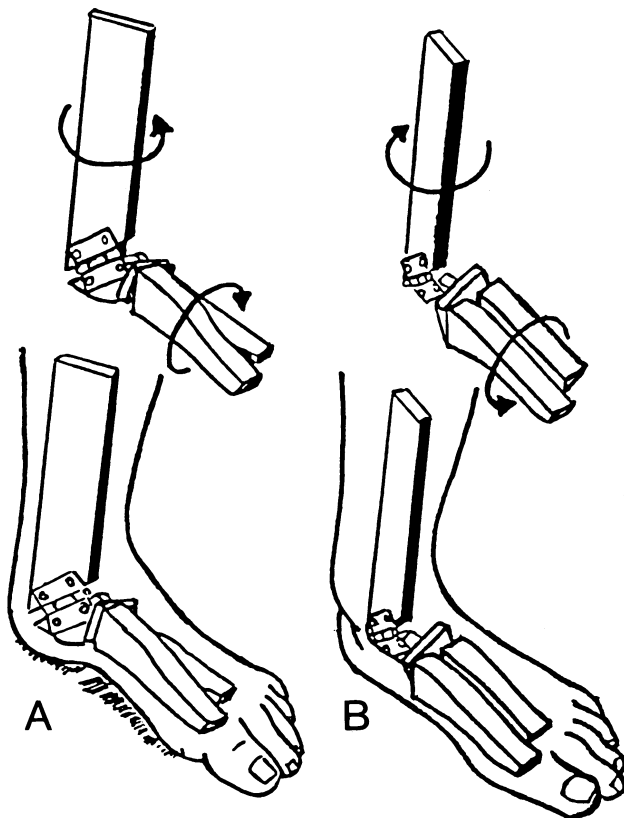


Figure 3. *A*, Illustrates external shank rotation generating supination of the subtalar joint. *B*, Illustrates internal shank rotation generating pronation of the subtalar joint. (Adapted and reproduced by permission from V. T. Inman. *Biomechanics of the Foot and Ankle*. DuVries' *Surgery of the Foot*. 5th ed. St. Louis: CV Mosby, 1986.)

of the lumbar spine. This, in turn, generates mechanical stress to the lumbar facets and SI joint, causing irritation to the nerve complex. The diagnostician can quickly ascertain the biomechanical soundness of the lower limb by watching the patient walk. Using the inner longitudinal arch (ILA) as his criterion, the contour of the ILA should not change from sitting to walking. If the ILA prolapses during gait, excessive subtalar joint pronation is diagnosed. If one limb pronates more than the other, the pelvis drops the foot undergoing the greatest range of pronation. This pelvic tilt will place traction on the afferent nerves and, in time, inflammatory changes are seen pathognomonic of chronic low back sufferers.

MATERIALS AND METHODS

In our sample study, biomechanical examinations were performed on all chronic low back sufferers following the norms established by Root et al. (13). The asymmetry in pronation patterns were evaluated dynamically in gait analysis and statistically by measuring

casts associated with excessive forefoot pronation patterns (again following the norms set up by Root et al.) The measurement reflected the amount of forefoot varum in degrees relative to the posterior bisection of the os calcis (Figure 4). Pelvic lists and associated leg length discrepancies were evaluated as follows: a) standing radiographs using either the posterosuperior iliac spine or the inferior-most aspect of the SI articulation as anatomical landmarks for comparisons; b) measuring the distance between the posterosuperior iliac spine and the internal malleolus in a supine position with feet perpendicular to the shank; and c) clinically observing leg length discrepancies in a prone vs. supine position.

RESULTS

In our preliminary study of 97 low back patients, 95 were excessive pronators (pronating more than 6° during stance phase of gait). Of the 95 excessive pronators, 81 exhibited asymmetrical gait patterns. Seventy-five of the 81 asymmetrical pronators exhibited a static pelvic list, 70 towards the foot undergoing the greatest amount of pronation (Table 1). Seventy-four of the 75 patients with a static pelvic list had a concomitant abducted (out-toeing) gait pattern. When these patients were placed in a rectus gait pattern (feet straight forward), 63 exhibited moderate-to-severe lateral instability. Sixty of the 75 patients had neurological symptoms

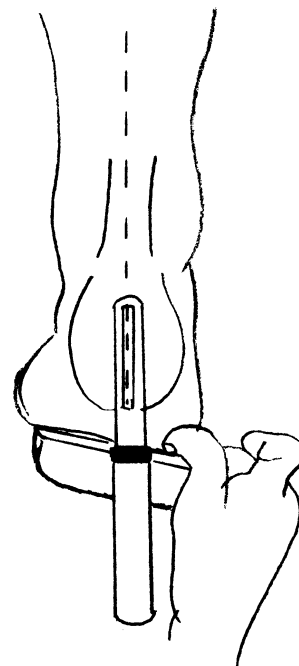


Figure 4. Forefoot varum plantar aspect of the forefoot is inverted relative to the posterior bisection of the calcaneus.

on the functionally short side. Of the 75 patients with a static pelvic list, 68 exhibited a LLD while prone, but no LLD while supine. While prone, the abdomen prevents the table's surface from affecting the position of the pelvis. However, in a supine position, the pelvic list is attenuated by the concomitant slight extension of the hips. This places traction on the hip flexors, which tilts the pelvis anteriorly while the tip of the sacrum is pushed forward. This leads to rotation at the SI joints (14), leveling the static pelvic list and obliterating the apparent LLD. A true anatomical LLD (ALLD) was differentiated from a functional LLD (FLLD) by measuring and comparing the distance between the anterosuperior iliac spine and the medial malleolus. Asymmetry of more than $\frac{3}{16}$ th of an inch was diagnosed as an ALLD. The precise use of this technique had a high correlation of radiographic reliability. The differentiation is important in treatment because only ALLD are amenable to heel lifts. Using a heel lift with FLLD will maintain the pelvic list and compound the symptomatology (Table 2).

The high correlation between excessive pronation and low back pain is apparent; 96% of the chiropractic patients were pronators. The high correlation (92%) between static pelvic lists and asymmetrical pronation patterns is consistent with our model. The effect of static pelvic lists on gait patterns was well illustrated when the angle of gait was altered from abduction to rectus, 84% of the patients with a list experienced lateral instability towards the short side. This suggests that limb abduction is a compensatory mechanism used to attenuate the lateral instability generated by the pelvic list.

All 81 asymmetrical pronators were placed in functional orthotics followed by an intensive short-term (2–3 wk) chiropractic manipulative program. Functional orthotics are devices that control the range of subtalar joint motion and prevent excessive internal shank rotation; i.e., more than 8° of stance phase pronation. The type of orthotic (hard or soft) is not as critical as how the orthotic is constructed. A functionally efficient orthotic must be fabricated around a neutral position cast (negative). A neutral position cast is obtained by casting the patient in a nonweight-bearing position, holding the foot where the subtalar joint is neither supinated nor pronated, while the cast material hardens.

Six month follow-up was as follows: a) 78 of the 81 patients related a moderate-to-complete reduction in low back symptoms, both in intensity and frequency of attacks; b) 63 of the 81 patients were still asymptomatic 6 months after their last podiatric or chiropractic ap-

TABLE 1. Static list (pelvis is *always* tilted towards the same side)

Condition	Number of patients					
	65	4	3	1	1	1
Static list	X	X	X	X	X	X
Dynamic list						
Asymmetrical pronation pattern	X	X	X	X	X	X
Excessive range of pronation	X	X	X	X		
Normal range of pronation					X	X
List towards foot pronating MORE	X	X			X	
List towards foot pronating LESS			X	X		X
Prone position only	X		X			
Supine and prone positions		X		X	X	X
Asymmetrical + excessive range of pronation						
Pelvic list toward foot pronating more: 69						
Pelvic list toward foot pronating less: 4						
Asymmetrical + normal range of pronation						
Pelvic list toward foot pronating more: 1						
Pelvic list toward foot pronating less: 1						

TABLE 2. Dynamic list (pelvic tilt is inconsistent)

Condition	Number of Patients					
	1	1	5	2	1	1
Static list						
Dynamic list	X	X	X	X	X	X
Asymmetrical pronation pattern	X	X				
Symmetrical pronation pattern			X	X	X	X
Excessive range of pronation	X	X	X	X		
Normal range of pronation					X	X
List towards foot pronating MORE	X					
List towards foot pronating LESS		X				
Prone position only	X	X	X		X	
Supine and prone positions				X		X

No meaningful correlations in above data indicating additional variables. (Hypermobility SI joints do not follow the pelvic list model. The authors believe frank structural changes in the vertebral column (e.g., herniated disk) play a major role in dynamic lists.)

pointment. Only two of the 63 asymptomatic patients exhibited a recurrence of the pelvic list; c) of the 15 patients experiencing a return of mild-to-moderate back symptoms, 13 were originally diagnosed as having asymmetrical gait patterns with no pelvic list. Only 2 of the 15 exhibited a static pelvic list; however, both tilts were towards the foot undergoing the least amount of pronation (atypical pattern).

DISCUSSION

Orthotics were used to eliminate excessive foot and limb rotation while manipulative therapy was used to reduce the pelvic list. We believe that by eliminating one of the major determinants for a static pelvic list

(asymmetrical pronation), chiropractic adjustments will last for longer periods of time. The 97 patients in this preliminary study were all chronic low back sufferers.

Forefoot varum deformity (forefoot supinatus) was present in 92% of the patients with a static pelvic list. Straus (15) originally described this structural anomaly as an ontogenetic retention in the torsional development of the talar neck probably occurring within the third trimester of the developing fetus. The topography presented in forefoot varum deformity is illustrated in Figure 4. When the subtalar joint is held in its neutral position and the midtarsal joint is maximally dorsiflexed, the plantar surface of the forefoot is twisted inward (varum) relative to the posterior bisection of the heel bone (calcaneus). At midstance, forefoot varum introduces limb instability by decreasing the amount of foot-to-ground contact. In order for the medial plantar margin of the forefoot to reach the ground (a functionally stable relationship), the foot must roll excessively inward (e.g., excessively pronate).

In a stable foot structure (one which does not generate excessive foot pronation), when the subtalar joint is held in its neutral position and the midtarsal joint is maximally dorsiflexed, the plantar surface of the forefoot is perpendicular to the posterior bisection of the calcaneus (Figure 5). This heel-to-forefoot relationship provides limb stability at midstance because the entire plantar surface of the foot contacts the ground.

Of the 81 asymmetrical pronators in our study, 67 were diagnosed as asymmetrical forefoot varum (the amount of inward "twist" varied between the two feet). Of statistical significance, 65 of the 67 patients with forefoot varum deformity exhibited a static pelvic list towards the foot with the greatest amount of inward rolling. Orthotics eliminate medial instability by posting (wedging) the forefoot. Wedging increases the surface contact area between the metatarsal arch and transverse plane by "building" the ground up to the foot (Figure 6). The pedal structure is now stable against the pull of gravity and excessive pronation does not occur.

The proposed pathodynamics associated with list-induced sciatic is as follows: a) the forward-downward rotation of the SI joint partially collapses the greater sciatic notch; b) the sciatic nerve is compressed between the piriformis muscle (superiorly) and the sacrospinous ligament (inferiorly); and c) chronic compression of the sciatic nerve produces the triad of inflammation, numbness, weakness and finally paralysis. In many cases, the sciatica associated with a static pelvic list can be attenuated by having the patient contract their gluteus maximus. This maneuver opens the greater sciatic notch by

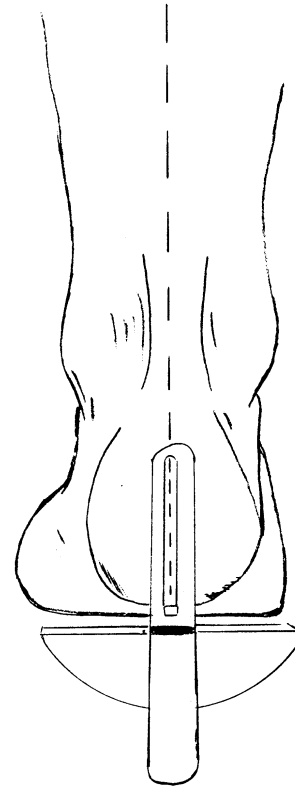


Figure 5. Stable adult structure: plantar aspect of forefoot is perpendicular to the posterior bisection of the calcaneus.

tilting the sacrum posteriorly, thereby releasing the pressure on the sciatic nerve. Subjectively, the patient relates immediate relief.

Although the above study involved only 97 patients with a very short follow-up report (6 months), the results were significant. We believe that the concurrent use of orthotics and manipulation is responsible for their success: 77% of the sample study was asymptomatic (74% with no pelvic list) 6 months after their last appointment. Of those still experiencing pain, 80% (12 of 15) did not have a static-type pelvic list. We suggest that once the pelvic girdle is aligned, orthotics maintain the functionally efficient position, allowing the chiropractic physician to obtain more permanent results.

Radiographically, the forward downward rotation of the SI joint is demonstrated by the relative position of the posterosuperior iliac spines (PSIS). (If the PSIS are not radiographically apparent, the caudal aspect of the SI joints may be used.) The PSIS rotates upward (anterosuperior iliac spine (ASIS) downward) on the side undergoing the greatest amount of pronation. This concept is easily visualized by placing both hands vertical to the ground, thenar surfaces facing one another, with the thumbs pointing towards the reader. If the

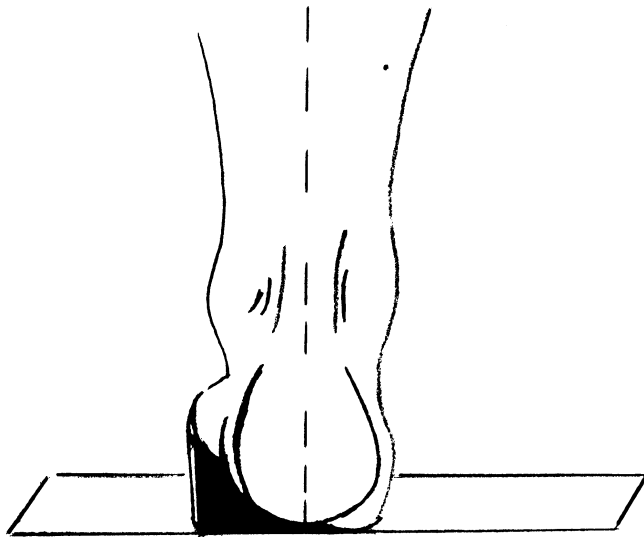


Figure 6. Forefoot-wedging medial post, which increases stability between the forefoot and weight bearing surface.

fifth finger represents the ASIS, the thumb represents the PSIS. A static pelvic list on the left side is represented by rotating the palm of the left hand slightly forward away from the reader. The left thumb (PSIS) is now cephalic (superior) to the right thumb. In every case where a static pelvic list was diagnosed and the LLD was present on the day the weight-bearing AP pelvic views were taken, the PSIS was radiographically cephalic on the side undergoing the greatest amount of overpronation.

At birth the sacroiliac joint is an amphiarthrodial articulation. In a mechanically stable gait pattern, the SI remains a slightly movable joint throughout life. However, if overpronation is present, the vertical pull of gravity on the prolapsing limb eventually introduces instability in the SI joint. The SI joint becomes a diathrosis. Only a movable joint will list. A static pelvic list spontaneously reduces itself more frequently in the adolescent because the list is not as great as in the adult. Clinically, a pelvic list introduces lateral instability away from the side undergoing the greatest amount of overpronation, i.e., a vertical displacement downward of the shoulder and hip. Subjectively, the patient is aware of an inconsistent "clumsy" gait when walking arm in arm (e.g., walking into a partner).

The practitioner must address the following when evaluating LLDS: a) is there a leg length discrepancy present; b) does the amount vary from a prone to supine position; and c) on different examination dates, is the leg length pattern consistent? "Eye-balling" the leg length pattern is appropriate for establishing the differential diagnosis (FLLD vs. ALLD). If an ALLD is

diagnosed, a heel lift is fitted to stabilize the base of support. This necessitates an exact determination of the leg length discrepancy. If a FLLD is diagnosed, the LLD is secondary to the pelvic instability. Attenuating the pelvic list resolves the LLD. A heel lift is not used, thus, accurate measurements are not required.

Chondromalacia or Runners Knee

In a retrograde fashion, excessive subtalar joint pronation generates excessive internal shank rotation. Inman and Mann (9) demonstrated that the amount of shank rotation generated by foot pronation is determined by the spatial orientation of the subtalar axis. As the subtalar axis becomes more vertical, internal limb rotation increases. For example, if the subtalar axis is perpendicular (90°) to the ground, each 1° of pronation will produce 1° of internal shank rotation. Conversely, if the subtalar axis is parallel to the ground, each degree of foot pronation produces practically no internal leg rotation. Hence, excessive retrograde internal shank rotation is a function of excessive subtalar joint pronation and the spatial orientation of the subtalar joint's axis of rotation. In pronators, the tibia (shank) is internally rotating faster than the femur. This asynchronous rotation pattern can dramatically twist the knee and adjacent soft tissue compartments. We theorize that asynchronous rotation of more than 4° – 6° is one of the primary mechanical dysfunctions responsible for an obliquely tracking patella. When the patella tracks obliquely across the femoral epicondyles toward the tibial tubercle and back again, gradual erosion of the cartilaginous surface interfacing the patella and femur occurs. Subjectively, the patient may complain of pain along the outer or inner margins of the knee cap or underneath the patella (nearly always associated with activity). Clinically, pain may be elicited upon palpation of the peripatellar margins, and/or crepitation noted upon passive extension of the knee joint. This syndrome is referred to as chondromalacia or runner's knee. The body attempts to reverse this mechanical dysfunction by splinting the knee joint (tightening the lateral and medial hamstrings and the tensor fascia lata) and/or attenuating the asynchronous rotation by decelerating shank rotation (using the posterior tibialis muscle, e.g., posterior shin splints) (16).

CONCLUSION

Based on this preliminary study, we have presented a clinical classification of leg length discrepancies: a) ALLD, in which one leg is anatomically longer than the other leg; and b) FLLD in which the pelvis has tilted. Pelvic lists are subcategorized as static, in which

the pelvic list is consistent on one side, and dynamic, in which the pelvic list varies from side to side. A correlation factor of 0.97 has been noted between asymmetrical pronators and static pelvic lists. A correlation factor of 0.92 has been noted between forefoot varum deformity and static pelvic lists. A correlation factor of 0.77 has been noted between attenuation of back symptoms and wearing orthotics.

We have also presented a pelvic list model delineating the pathomechanical events linking asymmetrical pronation patterns with static pelvic lists. Excessive pronation functionally shortens the limb by dropping the inner longitudinal arch. If the depression of the ILA is chronic and not symmetrical (from one foot to the other) a pelvic list can occur. A second biomechanical model has been proposed linking excessive pronation with chondromalacia.

Two types of pelvic lists have been identified: static and dynamic. The dynamic list does not follow the pelvic list model, indicating a different set of biomechanical events. The static pelvic tilt has a high statistical correlation to asymmetrical pronation patterns and (according to the authors) is one of the primary causes of LLDS. Treatment is based on controlling the excessive limb pronation, thus improving the prognosis for maintaining SI alignment.

The clinical data collected in this study seems to collaborate with our model. Even though the preliminary study is based on a small sample size, the need for further evaluation is compelling.

REFERENCES

1. Root ML, Weed JH, Sgarlato TE, Bluth DR. Axis of motion of the subtalar joint. *JAPA* 1966; 56:149-155.
2. Inman Verne. The joints of the ankle. II. Biomechanics of the subtalar joint. Baltimore: Williams & Wilkins, 1976.
3. Sammarco JG. Biomechanics of the Boot. In: Frankel VH, Nordin M eds. Basic biomechanics of the skeletal system. Philadelphia: Lea & Febiger, 1980: 202-204.
4. Levens AS, Inman VT, Blosser JA. Transverse rotation of the segments of the lower extremity in locomotion. *J Bone Joint Surg* 1948; 30A:859.
5. Wright DB, Desai SM, Henderson WH. Action of the subtalar and ankle joint complex during the stance phase of walking. *J Bone Joint Surg* 1964; 46A:361.
6. Elftman H. The transverse tarsal joint and its control. *Clin Orthop* 1960; 16:41.
7. Zitzlesperger S. The mechanics of the foot based on the concept of the skeleton as a statically indetermined space framework. *Clin Orthop* 1960; 16:47-63.
8. Levens AS, et al. Transverse rotation of the segments of the lower extremity in locomotion. *J Bone Joint Surg* 1948; 30A:859.
9. Inman VT, Mann RA. Biomechanics of the foot and ankle. In: Inman, VT ed. DuVries' surgery of the foot. Ed. 3, St. Louis: CV Mosby, 1973.
10. Ryker Jr, NJ. Glass walkway studies of normal subjects during normal level walking. Prosthetic Devices Research Project Institute of Engineering Research, University of California, Berkley. Series II, Issue 20. The Project, Berkley, 1952.
11. Houtz SJ, Fischer FJ. Function of leg muscles acting on foot as modified by body movements. *J Appl Physiol* 1961; 16:597-605.
12. Jones RL. The human foot. An experimental study of its mechanics, and the role of its muscles and ligaments in the support of the arch. *Am J Anat* 1941; 68:1-39.
13. Root ML, Orien WP, Weed JH, Hughes RJ. Biomechanical examination of the foot. 1st Ed. Los Angeles: Clinical Biomech Corp, 1971.
14. Kapandji IA. The physiology of the joints. Effect of posture on the joints of the bony pelvis. New York: Churchill-Livingstone, 1974; 3:70.
15. Straus Jr, WL. Growth of the human foot and its evolutionary significance. *Contrib Embryol* 19, 1927; 101:95.
16. Sutherland DH. An electromyographic study of the plantar flexors of the ankle in normal walking on the level. *J Bone Joint Surg* 1966; 48A:66-71.